Alternobaric vertigo in sportdivers

Klingmann C[1], Knauth M[2], Ries S[3], Tasman AJ[1]

Dr. med. Christoph Klingmann
HNO Universitätsklinik Heidelberg

Im Neuenheimer Feld 400
69120 Heidelberg, Germany
www.taucherprechstunde.de

christoph_klingmann@med.uni-heidelberg.de

1: Department of Otorhinolaryngology, Head & Neck Surgery, University of Heidelberg, Germany
2: Department of Neuroradiology, University of Göttingen, Germany
3: Department of Neurology, Eberbach, Germany

Introduction:

Alternobaric vertigo (AV) is a common manifestation of vertigo in divers. About one third of divers report having had alternobaric vertigo during their diving career. Pressure differences in both middle ears are suspected to influence the firing rate of the vestibular nerve that leads to the typical symptoms. The purpose of this study was to evaluate the prevalence of AV in a group of sport divers and to measure whether caloric videooculography, tympanometry, brainstem response audiometry (BERA) or MRI scan show any abnormalities in divers who suffer AV.

Material and Methods

We examined 64 sportdivers that took part in previous studies about brain lesions and transcranial doppler sonography. They answered a questionnaire about vestibular symptoms in the past and had the following examinations: microscopic otoscopy, caloric videooculography, tympanometry, brainstem evoqued response audiometry and an mri scan of the brain.

Results

One diver was found to have a retrocochlear tumour and was excluded from evaluation. Of 63 divers (17 female / 47 male) with an average diving experience of 650 dives and an average age of 37 years, 27% reported having had alternobaric vertigo. The vertigo lasted between 5 and 240 seconds and occurred between once in a divers lifetime and every fifth dive. The caloric videooculography showed pathologic results in 5 divers (one with AV / 4 without AV, not significant).

Tympanometry was normal in all divers.

BERA was abnormal in the diver with the retrocochelar tumour. Comparing the interpeak latencies I-V, I-III and III-V showed no significant differences between divers with and without AV. MRI scan of the brain stem was normal in all divers with and without AV. There were no brain lesions in the divers with AV.

Discussion

Alternobaric Vertigo is a common manifestation of vertigo in sport divers. We tried to find out whether there are some significant differences in caloric videooculography, tympanometry, BERA or MRI scanning of the brainstem. Significant differences would have given a prognostic diagnostic tool to find out if a diver suffers AV.
As we didn't find any differences in our test results we can't offer a prognostic diagnostic test.

Conclusion

Alternobaric vertigo is a common phenomenon in sport divers. The first manifestation of this kind of vertigo especially in beginner divers can lead to diving accidents. Unfortunately we could not find a prognostic diagnostic tool to establish whether a diver will experience alternobaric vertigo or not.

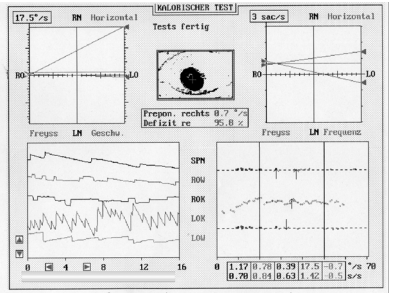

Caloric Videooculography: complete abscence of a vestibular response to either warm and cold stimulation of the right horizontal vestibular organ. The diver never having had vertigo during diving.

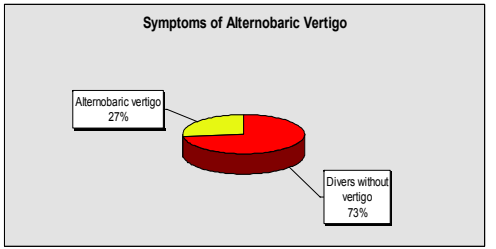

One third of the divers reported symptoms of alternobaric vertigo.